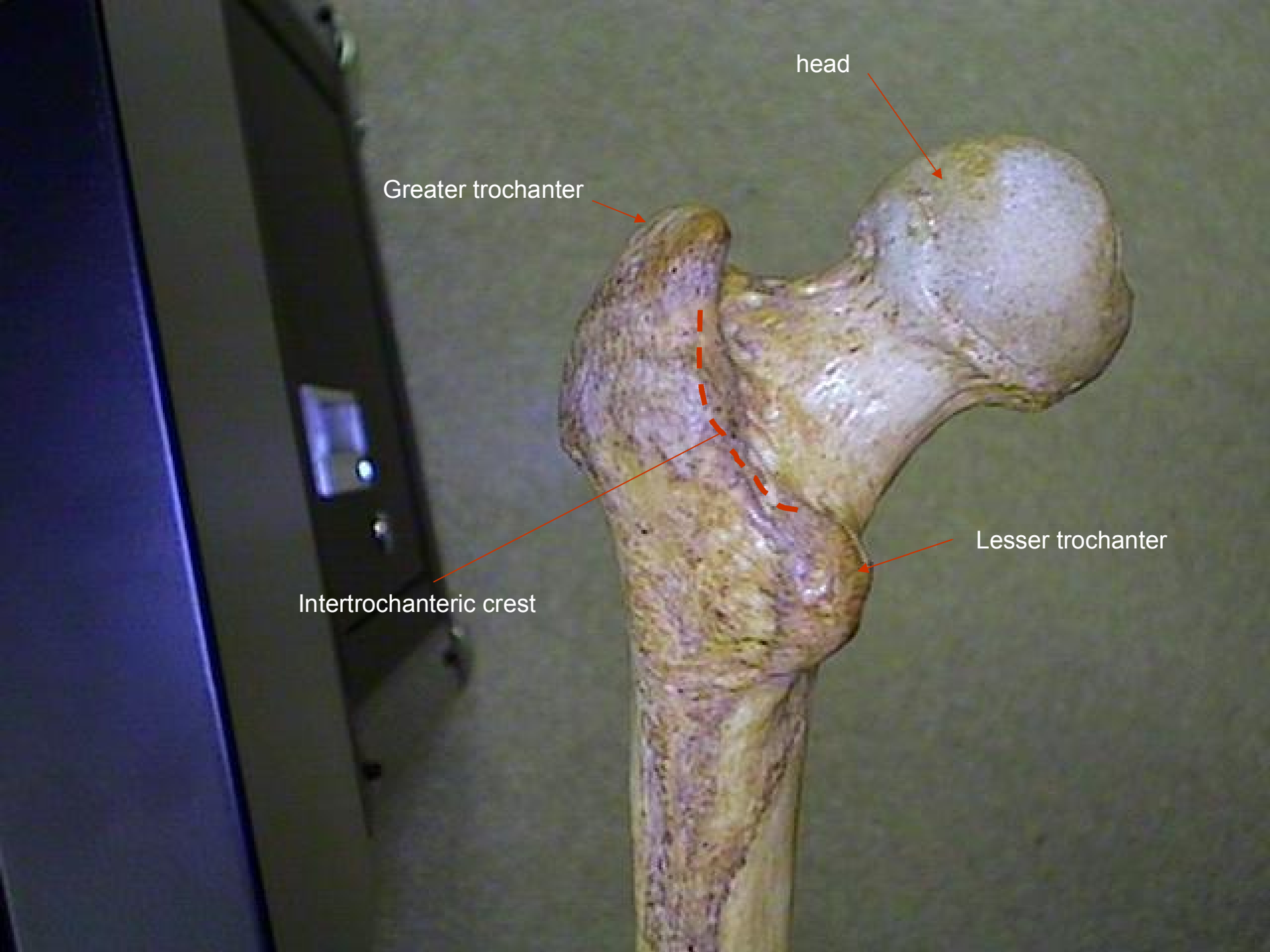


# Skeletal Bones, Femur

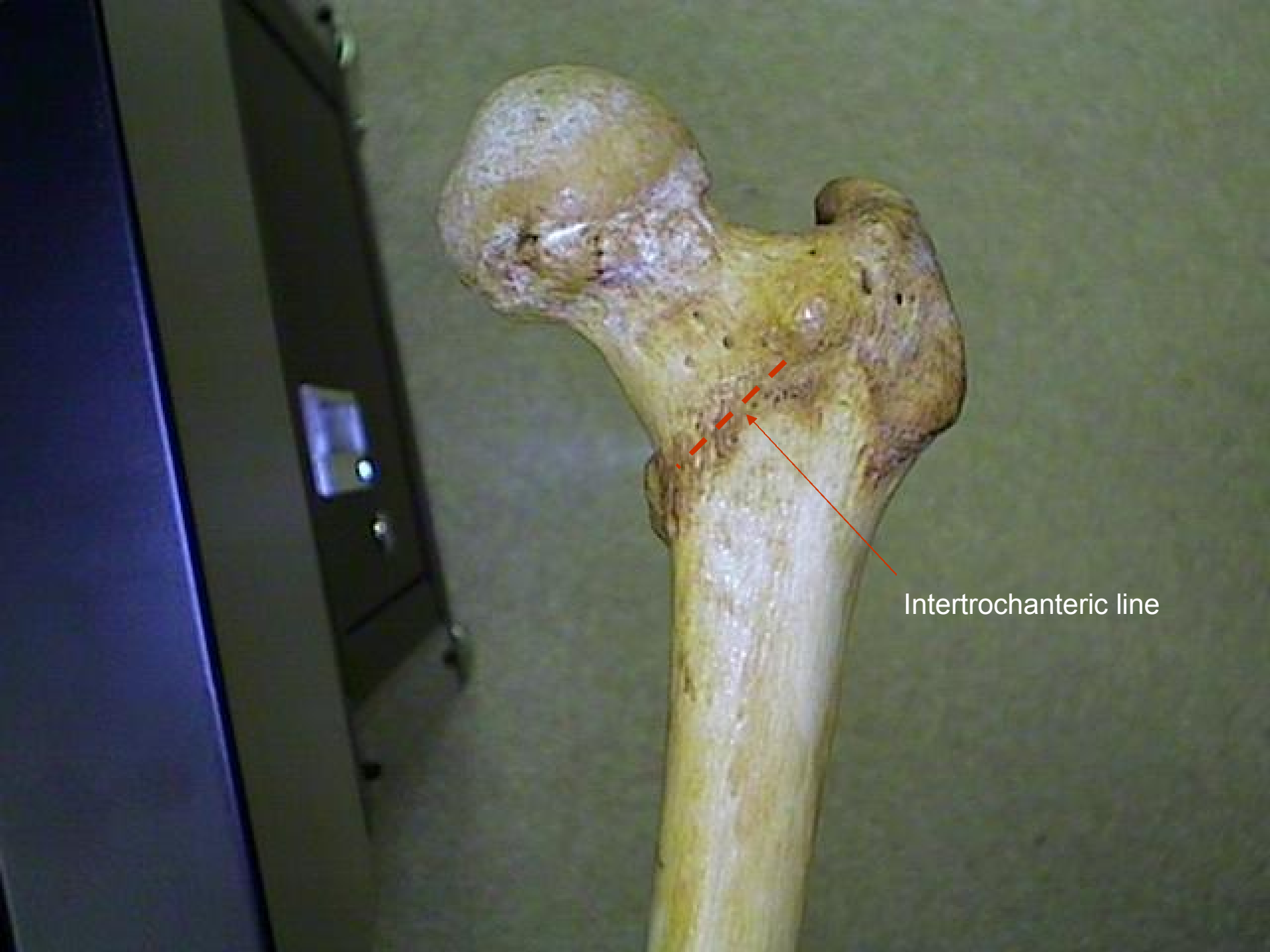

head

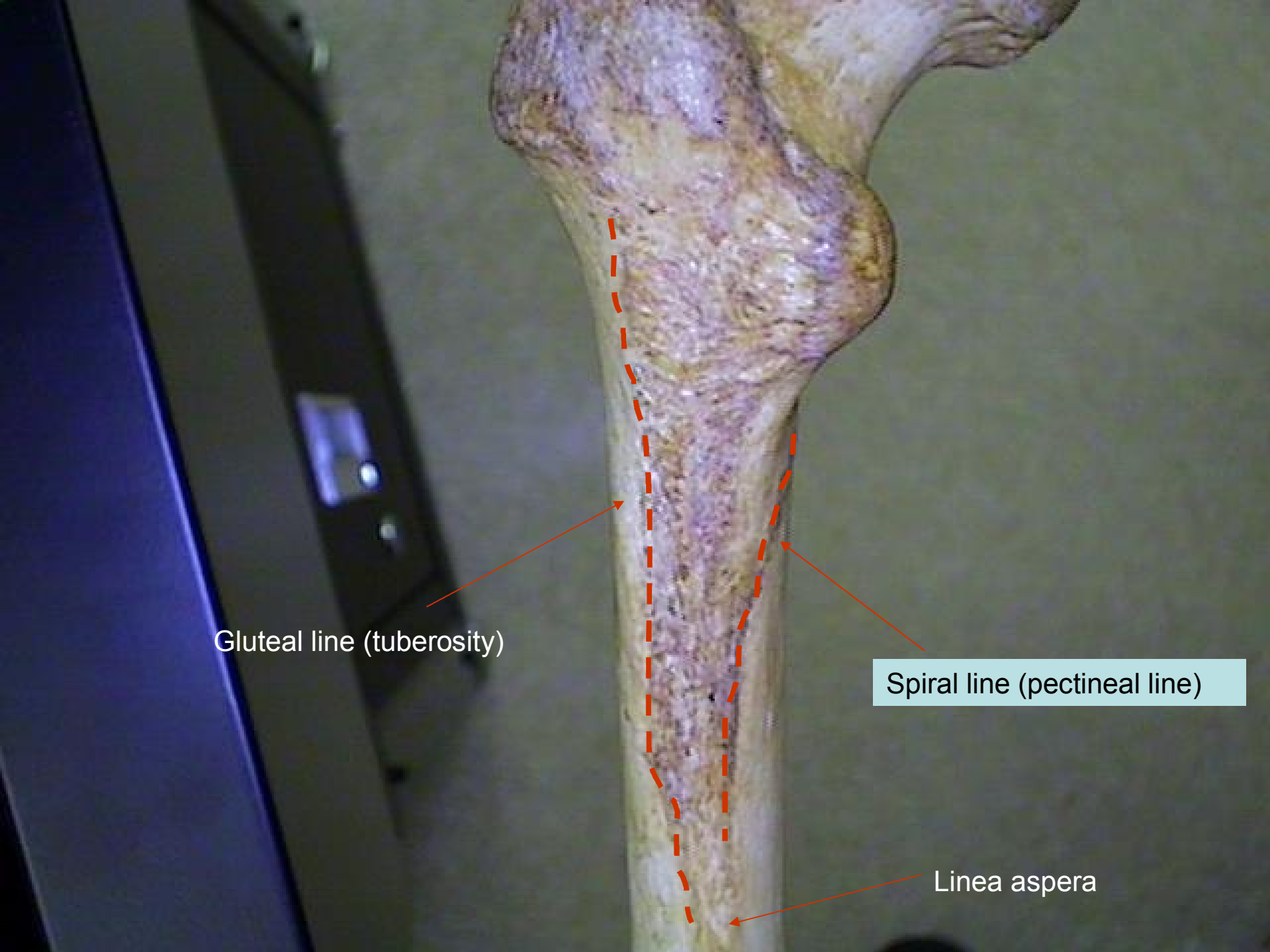
Greater trochanter

Lesser trochanter

Intertrochanteric crest



Intertrochanteric line



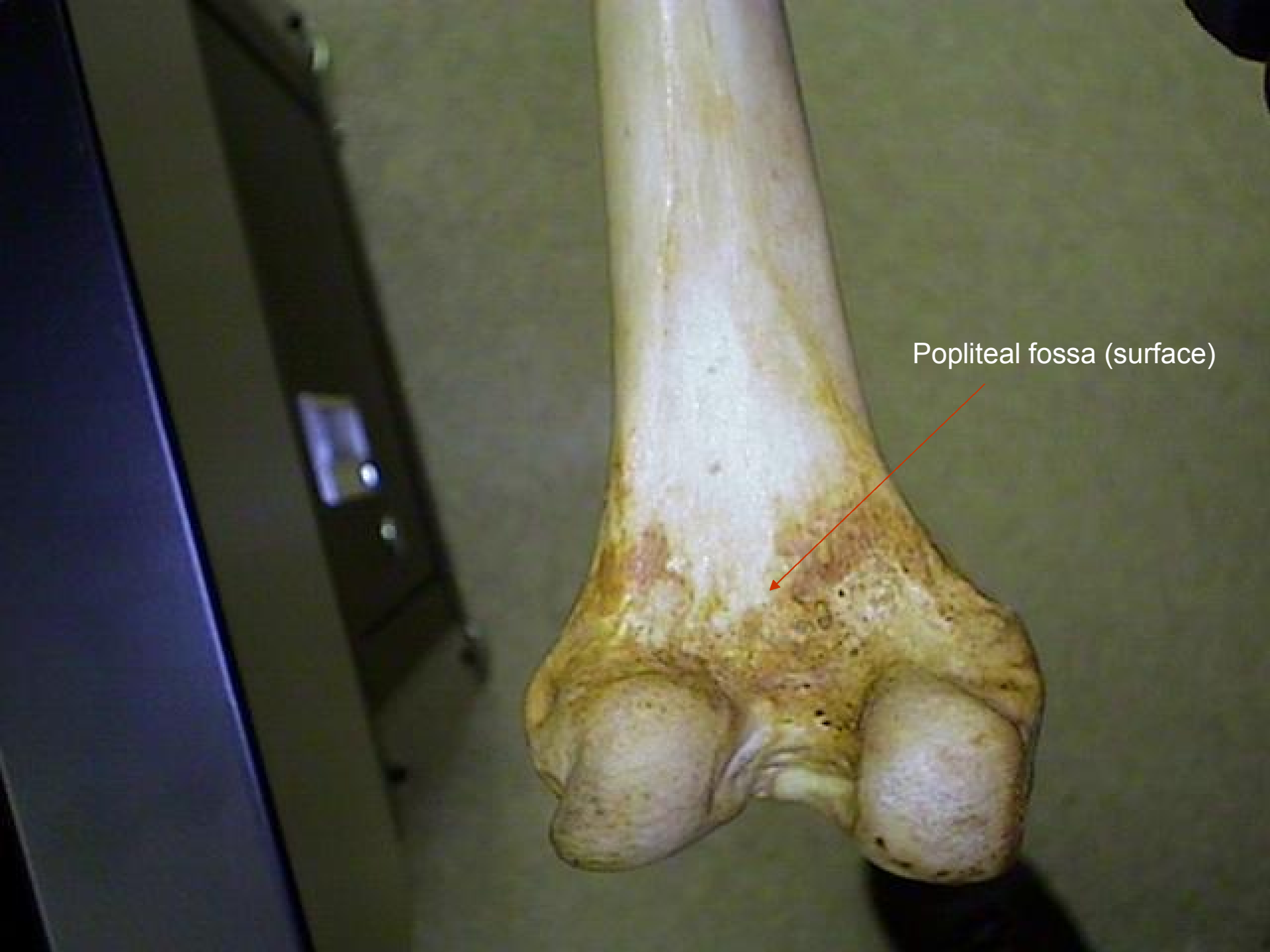Gluteal line (tuberosity)

Spiral line (pectineal line)

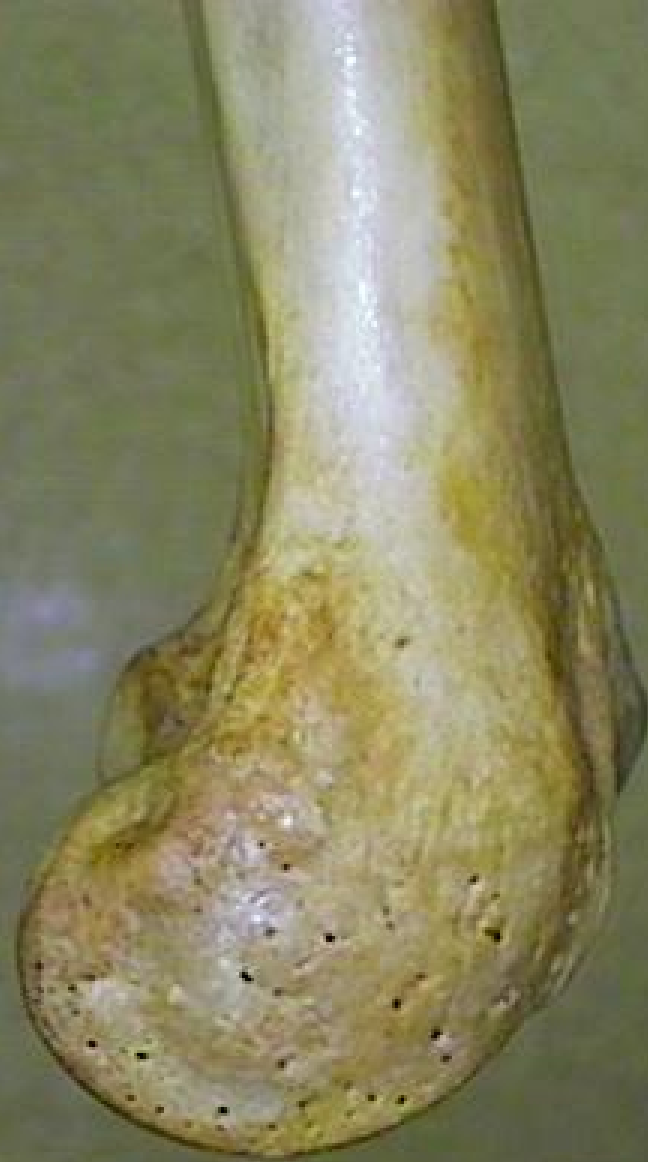Linea aspera

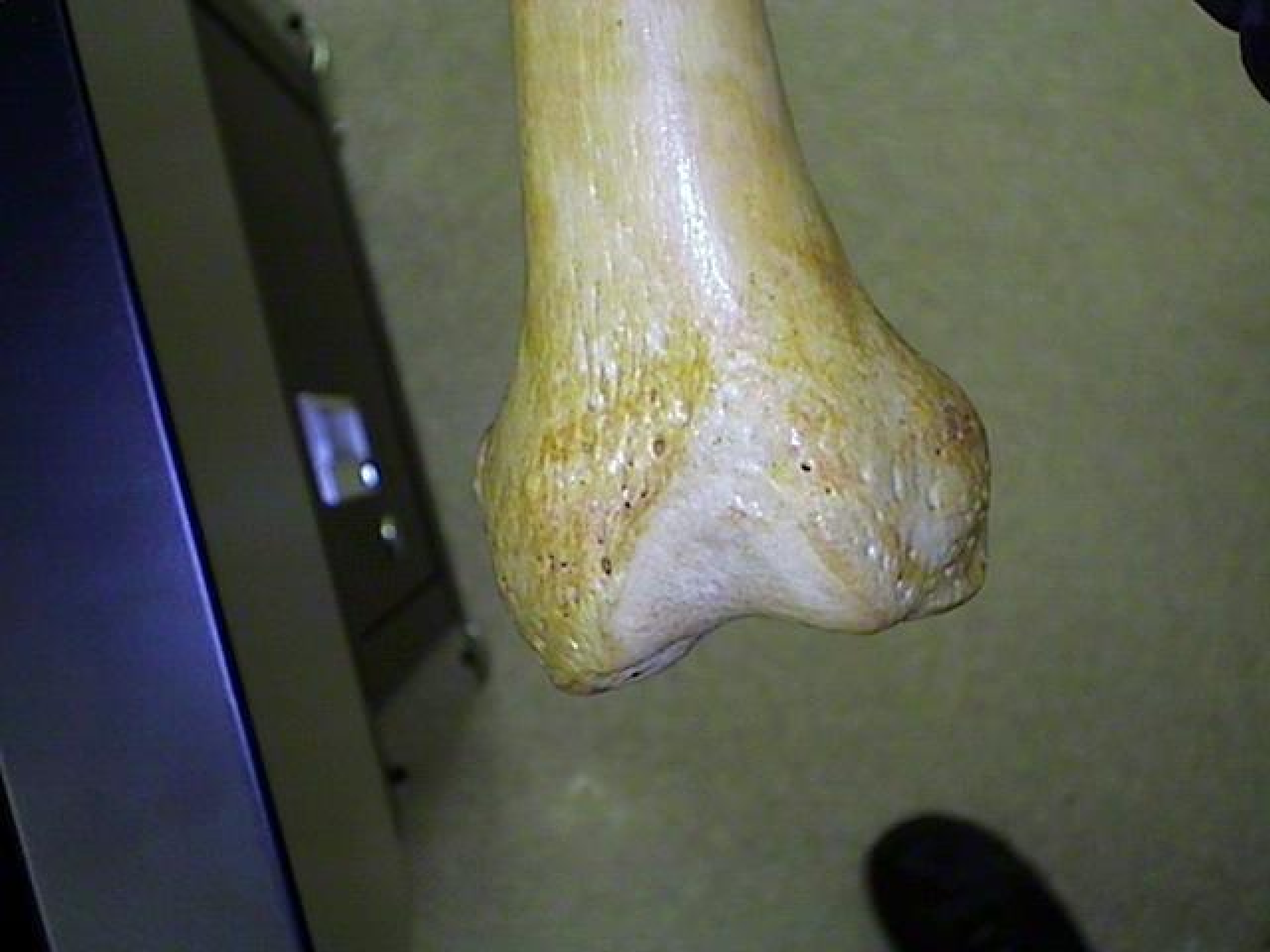

Linea aspera



Popliteal fossa (surface)





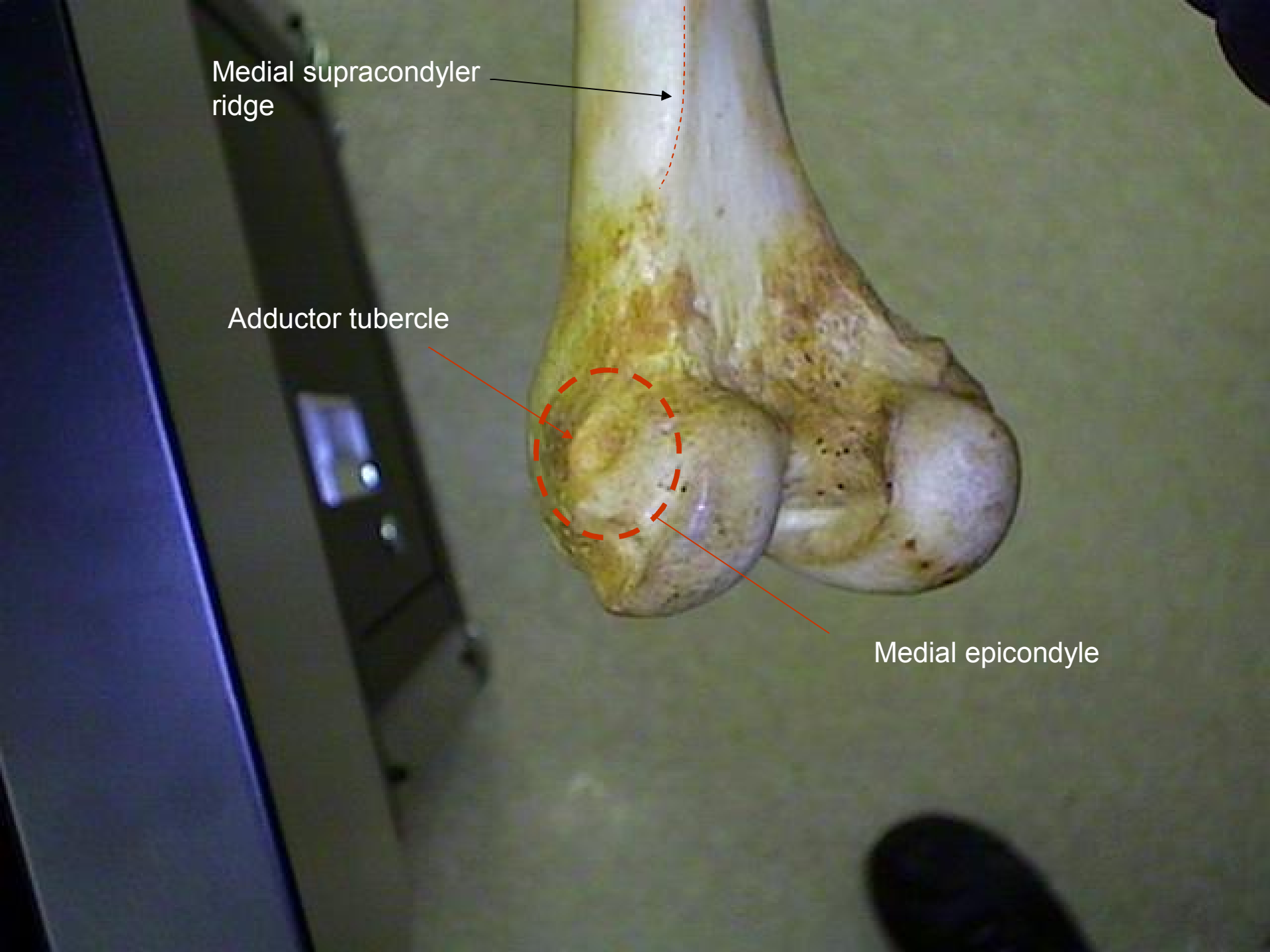
Medial supracondyler ridge

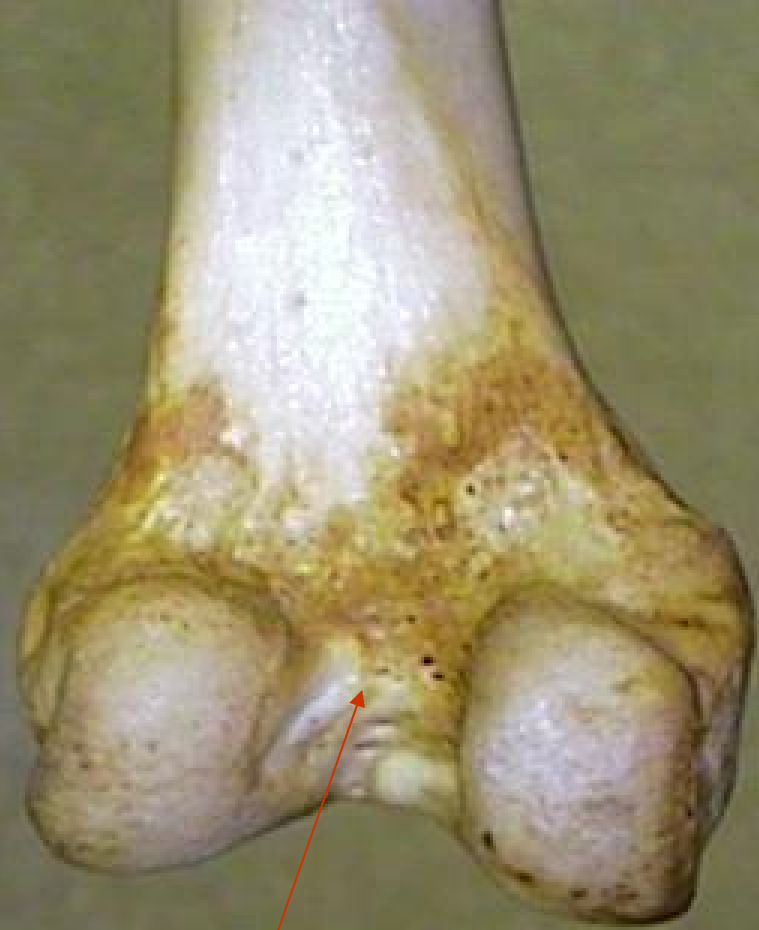

Adductor tubercle



Medial epicondyle





Intercondyler fossa



Gluteal line

Linea aspera  
(pecteneal line)

Fovea capitis







